

Outbreak of Neurologic Enterovirus Type 71 Disease: A Diagnostic Challenge

Carlos M. Pérez-Vélez,^{1,3,a} Marsha S. Anderson,^{1,3,a} Christine C. Robinson,^{2,3} Elizabeth J. McFarland,^{1,3} W. Allan Nix,⁴ Mark A. Pallansch,⁴ M. Steven Oberste,⁴ and Mary P. Glodé^{1,3}

¹Department of Pediatrics, Section of Infectious Diseases, and the ²Department of Pathology, University of Colorado School of Medicine, and ³The Children's Hospital, Denver, Colorado; and ⁴Polio and Picornavirus Laboratory Branch, Division of Viral Diseases, National Center for Immunization and Respiratory Diseases, Centers for Disease Control and Prevention, Atlanta, Georgia

Background. Similar to poliovirus, enterovirus type 71 (EV71) causes severe disease, including aseptic meningitis, encephalitis, acute flaccid paralysis, and acute cardiopulmonary dysfunction. Large epidemics of EV71 infection have been reported worldwide.

Methods. After recognition of a cluster of cases of EV71 disease, we reviewed records of patients with EV71 disease who required hospitalization at The Children's Hospital in Denver, Colorado, from 2003 through 2005. The presence of enterovirus was detected by reverse-transcriptase polymerase chain reaction (PCR) and/or viral culture of specimens from multiple sources, and the virus was typed as EV71 using genetic sequencing.

Results. Eight cases of EV71 disease were identified in both 2003 and 2005. Fifty-six percent of patients with EV71 disease were ≤ 6 months of age (range, 4 weeks to 9 years). All 16 patients had EV71 central nervous system infection. Enterovirus PCR (EV-PCR) of cerebrospinal fluid specimens yielded positive results for only 5 (31.2%) of the 16 patients; all of these patients were < 4 months of age and had less severe disease. However, EV-PCR of upper respiratory tract specimens yielded positive results for 8 (100%) of 8 patients, and EV-PCR of lower gastrointestinal tract specimens yielded positive results for 7 (87.5%) of 8 patients.

Conclusions. An outbreak of neurologic EV71 disease occurred in Denver, Colorado, during 2003 and 2005. Likely, EV71 disease remains unrecognized in other parts of the United States, because EV-PCR of cerebrospinal fluid frequently yields negative results. EV-PCR of specimens from the respiratory and gastrointestinal tracts had higher diagnostic yields than did EV-PCR of cerebrospinal fluid. EV71 infection should be considered in young children presenting with aseptic meningitis, encephalitis, acute flaccid paralysis, or acute cardiopulmonary collapse. EV71 infection may be an underrecognized emerging disease in the United States.

Wild poliovirus disease has been eradicated from the developed world, and in 2006, only 1956 cases were identified [1]. Like poliovirus, enterovirus type 71 (EV71) can cause severe neurologic diseases, including acute flaccid paralysis (AFP), brainstem encephalitis, and acute cardiopulmonary collapse, as well as death [2–6]. EV71 was first isolated in California in 1969 from the stool sample from an infant with encephalitis [7]. Over the next 3 years, EV71 was isolated by culture of stool samples from an additional 19 patients in California. Thirteen (65%) of these 19 patients were < 5 years of age, and 1 patient died. Many researchers have

noted that young children are most susceptible to severe disease [5, 8].

Since the first report, there have been outbreaks of EV71 disease worldwide [5, 9–11]. The primary manifestation of EV71 infection during periods of epidemicity is hand-foot-and-mouth disease [11]. The largest reported outbreak of EV71 disease occurred in Taiwan (in 1998) and included 78 fatalities (34 were the result of laboratory-confirmed EV71 disease) [10]. The majority of deaths were attributable to cardiopulmonary failure resulting from brainstem encephalitis [12]. Because of the significant morbidity and mortality associated with EV71 disease, recognition of multiple cases in a community is concerning. This report describes an outbreak of EV71 disease, including 1 fatality.

Received 3 April 2007; accepted 2 July 2007; electronically published 13 September 2007.

Reprints or correspondence: Dr. Marsha S. Anderson, The Children's Hospital, 1056 E. 19th Ave., Box B-158, Denver, CO 80218 (anderson.marsha@tchden.org).

Clinical Infectious Diseases 2007;45:950–7

© 2007 by the Infectious Diseases Society of America. All rights reserved.

1058-4838/2007/4508-0002\$15.00

DOI: 10.1086/521895

The findings and conclusions in this report are those of the authors and do not necessarily represent the views of the Centers for Disease Control and Prevention.

^a C.M.P.-V. and M.S.A. contributed equally to this article.

METHODS

This study was approved by the institutional review board of the University of Colorado. Medical records of all patients with EV71 disease were reviewed. Clinical information abstracted included demographic characteristics, all clinical notes, and laboratory and radiologic findings.

After the recognition of multiple cases of EV71 disease in 2003, we developed written guidelines for recognition and recommended laboratory evaluation of suspected patients. These guidelines suggested that rectal, throat, and CSF samples be obtained from hospitalized patients with febrile illness and neurologic disease and tested for enterovirus by enterovirus PCR (EV-PCR) and/or viral culture. This information was widely circulated at our institution (The Children's Hospital, Denver, CO). The timing of specimen collection, type of specimens, and tests were determined by the treating physician. Cases were ultimately defined and identified by confirmation of EV71 in at least 1 patient sample at the Centers for Disease Control and Prevention (CDC; Atlanta, GA).

All patients who had ≥ 1 specimen that was positive for enterovirus by PCR or viral culture had at least 1 positive sample sent to the CDC for confirmation and enteroviral typing. In addition, all CSF samples of adequate volume from hospitalized patients who received any diagnosis and who had enteroviral testing ordered (whether PCR results were positive or negative) were sent to the CDC for confirmatory EV-PCR and molecular typing.

Virologic studies. The EV-PCR used at The Children's Hospital (TCH; Denver, CO) is a conventional, generic assay targeting the 5' untranslated region of the viral genome [13]. Specimens for viral culture were inoculated into human embryonic fibroblasts (MRC-5), human lung (A549) cells, and primary Rhesus monkey kidney cell tubes. Isolates exhibiting enteroviral cytopathologic characteristics were presumptively identified by indirect immunofluorescence using a "Pan-enterovirus" monoclonal antibody (Chemicon International). In 2005, all enteroviral isolates were also tested at TCH using an EV71-specific monoclonal antibody (Chemicon) before being forwarded to the CDC for confirmation. Isolates or specimens were then typed as EV71 at the CDC by sequence analysis of amplified products generated by PCR of the VP1 gene [14, 15]. Virus genotype was deduced by comparison with a reference sequence database, and phylogenetic analysis was performed using the Clustal X neighbor-joining method [16, 17]. CSF samples from all patients identified as having EV71 infection were tested by flavivirus PCR at the CDC.

Definitions. CSF pleocytosis was defined as a WBC count >10 cells/mm³ in a CSF sample. Meningitis was defined as the presence of CSF pleocytosis and/or a positive result of EV-PCR of a CSF sample. Encephalitis was defined as an alteration in the level of consciousness. AFP was defined as the acute onset

of loss of motor function in ≥ 1 skeletal muscle group (usually, the limbs), associated with absent or diminished reflexes in the affected muscle group(s).

Statistical analysis. Statistical analyses of differences were performed using the χ^2 test or Mann-Whitney *U* test for non-parametric comparisons.

RESULTS

Case identification. From January 2003 through December 2005, a total of 1047 patients had specimens submitted to TCH laboratory for physician-ordered enteroviral testing; 284 patients (27.1%) infected with enterovirus were identified. Specimens from 101 of these patients were available for typing; 16 cases of EV71 infection were confirmed by the CDC. Eight cases of EV71 infection were identified in 2003. No cases were found in 2004, despite heightened awareness; 8 cases were identified in 2005.

Figure 1 shows the epidemic curve. All 16 patients with EV71 disease resided in the Denver metropolitan area (population, 2.3 million; 6.8% of the population is <5 years of age) [18]. Fifteen patients were admitted to TCH, and 1 patient was hospitalized in a community hospital.

Table 1 summarizes the clinical features and outcomes of the 16 patients. Fifty-six percent of the patients were ≤ 6 months of age (range, 4 weeks to 9 years). Ten patients were male, and 6 were female. Two patients (patients 5 and 6) were cousins; patient 6 developed symptoms 2 days after contact with patient 5. Figure 2 shows the close genetic relationship of their isolates. One additional patient (not shown in table 1) was a cousin and household contact of patient 2. This additional patient was a 5-year-old girl who was hospitalized with aseptic meningitis 5 days after patient 2 was hospitalized. For the 5-year-old girl, the results of EV-PCR of a CSF specimen were negative, and no other specimens (e.g., throat or rectal swabs) were collected.

Most of the patients (12 of 16 patients) presented with >1 clinical syndrome attributable to EV71 infection (table 1). Patients presented with the following major clinical manifestations: meningitis (in 5 patients), AFP (3), fever (4), encephalitis (2), and acute cardiopulmonary dysfunction (2). Two patients who presented with encephalitis also had AFP (total of 5 patients with AFP). In 4 of the 5 patients with AFP, a single limb was involved; 1 patient had quadriplegia. Two patients (patients 15 and 16) experienced significant improvement in their motor function, and 3 remain with some degree of monoparesis. Acute cardiac dysfunction and pulmonary edema developed in 2 patients (patients 2 and 5), 1 of whom died on day 26 of illness. The patient who died was a 5-year-old girl with cardiopulmonary collapse and subsequent anoxic-ischemic brain injury, with eventual herniation. Patient 2 also presented with pulmonary edema and acute cardiac dysfunction, which both resolved with supportive

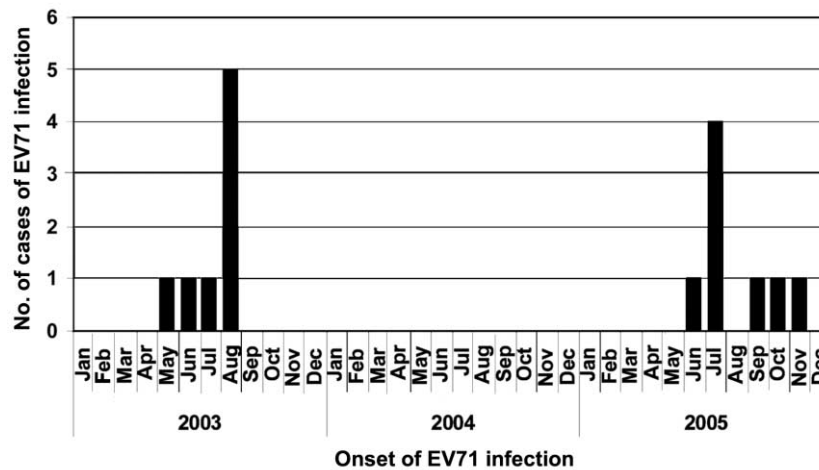


Figure 1. Month and year of onset of enterovirus type 71 (EV71) infection in an outbreak of EV71 disease in Colorado, in 2003 and 2005

care. He remains quadriplegic and dependent on mechanical ventilation >3 years after initial infection.

Diagnostic evaluation. Table 2 shows the virologic testing performed for the EV71-infected patients. All patients had CSF samples tested by EV-PCR at TCH, but only 5 (31.3%) of 16 results were positive. None of the patients with paralysis, nor the patient who died, had a positive result of EV-PCR of CSF samples, although the virus was detected in all of these patients by PCR of throat and/or rectal swab specimens. Nine patients had CSF pleocytosis, and only 1 of these patients had a CSF sample that was positive for enterovirus by EV-PCR (table 3). Eight patients had upper respiratory tract specimens submitted for testing, and EV-PCR results were positive for all 8 patients (100%). Eight patients had rectal swab specimens submitted for testing, and EV-PCR results were positive for 7 (87.5%) of the patients. An additional 2 patients had combined upper respiratory and/or rectal specimens submitted, and EV-PCR results were positive for both (100%) of these patients. Nine of 16 patients had enterovirus detected in >1 specimen, and 6 of 16 patients had enterovirus detected by >1 diagnostic technique (viral culture or PCR). Patient 4 had rhinovirus 16 recovered from a nasopharyngeal aspirate specimen. This patient also had EV71 detected in rectal and urine specimens.

Evaluations of CSF cell counts, glucose levels, and protein levels were performed for 14 patients (table 3). Protein levels were ≥ 40 mg/dL in 12 (85.7%) of 14 patients. All patients who had positive results of EV-PCR of CSF samples had some degree of contamination of the CSF by RBCs. Nine (64.3%) of 14 patients had CSF pleocytosis (2 patients had grossly bloody CSF; thus, no cell count was obtained), with RBC counts ranging from 11 cells/mm³ to 2075 cells/mm³.

For all 16 patients, the identity of the enterovirus detected was confirmed as EV71 by EV-PCR amplification of a portion of the VP1 gene, followed by sequencing. For 15 patients, the

sequences were of sufficient length and quality for genotype identification by phylogenetic analysis. The sequences from patients 1–15 were all EV71 genogroup C and related to viruses that have recently circulated worldwide (figure 2). The sequences from EV71 isolates obtained from patients in Colorado clustered into 3 groups. Five of the sequences from 2003 (patients 1, 2, 4, 7, and 8) clustered together, and the sequence in the isolate from patient 15 (from 2005) was also related to this group. Sequences for patients 5 and 6 clustered with other sequences in isolates obtained from Texas in 2003, and sequences in isolates obtained in 2005 from patients 9–14 also fit into this cluster. The sequence from patient 3 clustered with a sequence in isolates from Malaysia in 1997 and a sequence in isolates from Maryland in 2001.

Three of 5 children with AFP were tested for evidence of West Nile virus infection (for 2 patients, the serum IgM level was tested; for 1 patient, the CSF IgM level was tested), and all test results were negative. CSF specimens from all patients in this series had PCR results that were negative for flavivirus. Two children with AFP had received an initial diagnosis of “atypical” Guillain-Barré syndrome.

DISCUSSION

This report of 16 hospitalized patients with EV71-associated neurologic disease is noteworthy and concerning for several reasons. EV71 circulation appears to be increasing in the United States [19]. This is the first reported outbreak of EV71 disease in the United States in 20 years. During the 1987 US outbreak, there were 45 cases of EV71 disease (in Alaska, New Jersey, and Pennsylvania), 27 of which involved CNS manifestations [5, 20]. Similar to previous outbreaks of EV71 disease, the outbreak in Colorado persisted for >1 year, with significant morbidity and 1 fatality. Finally, results of EV-PCR of CSF samples were

Table 1. Clinical syndromes and outcomes in patients with enterovirus type 71 infection.

Patient	Date of onset of infection, month/year	Age	Sex	Presenting manifestation	Clinical syndrome						Outcome
					Meningitis	Encephalitis	Acute flaccid paralysis	Pulmonary edema ^a	Rash	Mouth ulcers	
1	5/2003	2 years	M	Meningitis	+	-	-	-	-	+	Recovered
2	6/2003	5 years	M	Pulmonary edema, cardiac dysfunction	+	+	+	+	-	-	Paralyzed, dependent on mechanical ventilation
3	7/2003	7 weeks	M	Fever	+ ^b	-	-	-	-	-	Recovered
4	8/2003	6 months	M	Acute flaccid paralysis	+	+	+	-	-	+	Monoparesis
5	8/2003	5 years	F	Pulmonary edema, cardiac dysfunction	-	+	-	+	-	-	Died on illness day 26
6	8/2003	2 months	F	Meningitis	+	-	-	-	+	-	Recovered
7	8/2003	3 month	M	Fever	+ ^b	-	-	-	+	-	Recovered
8	8/2003	4 weeks	F	Fever	+ ^b	-	-	-	-	-	Recovered
9	6/2005	9 years	M	Encephalitis	-	+	-	-	+	-	Recovered
10	7/2005	3 month	M	Meningitis	+	-	-	-	+	-	Recovered
11	7/2005	7 months	F	Acute flaccid paralysis	-	-	+	-	-	+	Monoparesis
12	7/2005	6 weeks	F	Meningitis	+	+	-	-	-	-	Recovered
13	7/2005	7 weeks	M	Meningitis	+	-	-	-	+	+	Recovered
14	8/2005	3 months	M	Fever	+ ^b	-	-	-	+	-	Recovered
15	10/2005	2 years	M	Encephalitis	+	+	+	-	-	-	Recovered
16	11/2005	2 years	F	Acute flaccid paralysis	+	-	+	-	-	-	Monoparesis
All, no. of patients with the syndrome/total no. of patients	13/16	6/16	5/16	2/16	6/16	4/16	...

NOTE. -, Syndrome not present; +, syndrome present.

^a Both patients with pulmonary edema also had acute cardiac dysfunction.

^b Designated as meningitis because of PCR results positive for CSF enterovirus (no pleocytosis observed).




Figure 2. Phylogenetic tree of enterovirus type 71 (EV71) strains. The phylogenetic tree depicts relationships among representative group C EV71 strains circulating worldwide from 1985 through 2005, including 15 of the 16 confirmed cases in Colorado. Phylogenies were reconstructed by the neighbor-joining method using sequences of the EV VP1 gene, as described in Methods. Patient 16 was excluded, because sequencing of the clinical material that was positive for enterovirus by EV PCR was unsuccessful. Note that the cases in Colorado cluster into 4 groups.

negative for 68.8% of our patients, and most diagnoses were made on the basis of results of EV-PCR of upper respiratory and/or lower gastrointestinal tract specimens.

In the United States, laboratory confirmation of enterovirus-associated neurologic disease is typically performed by PCR of CSF samples because of the greater sensitivity and rapid turnaround time, compared with culture [13, 21]. For enterovirus-associated neurologic disease other than EV71-associated disease, the sensitivity of EV-PCR of CSF samples is reported to be 76%–100% [13, 22–25]. However, CSF specimens may not be optimal for detection of EV71 by viral culture or PCR. CSF viral culture results for patients with EV71-associated neurologic disease are reported to be positive for only 0%–3% of cases [9, 26]. The sensitivity of EV-PCR of CSF samples from patients infected with EV71 is also poor. In a 2002 clinical study of an EV71-specific PCR of CSF samples, the yield was 0% (0 of 12 samples were positive for EV71) [27]. All patients in our study

had CSF samples tested by EV-PCR, and only 5 of 16 samples were positive for enterovirus. These results are similar to those reported in a study of paralytic polio, in which CSF viral cultures yielded positive results for only 35 (6.4%) of 543 patients [28]. Another study reported that only 1 of 29 patients with paralytic polio had poliovirus RNA detected by EV-PCR of CSF samples [29].

The reason that EV71 is difficult to detect in CSF samples is unclear. Possible explanations for this include the virus only transiently being present in CSF, a lower amount of virus being present in CSF, the enterovirus PCR assay used not having been optimized for detection of EV71, and/or different neuropathogenesis manifesting than those exhibited by other enteroviruses. Most laboratories use an enteroviral PCR designed for detection of the greatest number of serotypes. As new nucleic acid detection methods are developed, the ability to identify EV71 in CSF samples may improve. A recent study directly compared EV-PCR of CSF samples with a microchip method (DR. Chip Biotechnology). The microchip method detected enterovirus in 52% of CSF samples from EV71-infected patients, compared with a detection rate of 29% for CSF samples tested by EV-PCR [30]. All CSF samples that were positive for enterovirus at TCH were also positive by EV-PCR at the CDC laboratory.

In this study, all 5 patients with positive results of EV-PCR of CSF samples were <4 months of age, and most did not have CSF pleocytosis. Detection of enterovirus in CSF samples by EV-PCR in young children without pleocytosis is well recognized [31, 32]. Patients with positive results of EV-PCR of CSF samples had CSF samples collected significantly earlier during their illness, compared with patients who had negative results of EV-PCR of CSF samples (mean number of days after the onset of illness that samples were collected, 1.6 vs 5.6 days; $P < .01$). It is possible that EV71 was only transiently present in CSF samples and was only found in patients who had a lumbar puncture performed early during the course of illness [25].

All 5 infants who had positive results of EV-PCR of CSF samples had less severe disease. All of these infants were admitted to the hospital for fever, had short hospitalizations, and recovered without sequelae. Possible explanations for less severe disease during infancy include modification of the disease from the maternal antibody or that the disease is immune-mediated and immune responses in these infants were not as vigorous as those in older children [33].

There were 5 patients who presented with AFP, and 4 (80%) of these 5 patients experienced residual monoparesis. Of the 2 patients in this series with acute cardiac dysfunction and pulmonary edema, one died, and the other is dependant on mechanical ventilation and is quadriparetic. These results are similar to those recently reported by Chang et al. [34] in their study of the long-term neurologic sequelae associated with EV71 disease. In their series, 56% of the patients who presented

Table 2. Enteroviral PCR and culture results for patients with enterovirus type 71 infection.

Patient	Specimen											
	CSF		Blood		Throat		Rectal		Nasal wash		Other	
	PCR result	Culture result	PCR result	Culture result	PCR result	Culture result	PCR result	Culture result	PCR result	Culture result	PCR result	Culture result
1	–	+	...	+
2	–	...	–	+	+	+ ^a	...
3	+
4	–	...	Ind	...	+	– ^b	+	+	+	– ^b	+ ^c	...
5	–	...	Ind	...	+	–	+	–	...	+	– ^c , + ^d	...
6	+
7	+
8	+ ^e	+	...	+	–
9	–	+
10	–	+	+	...	+	+ ^f	...
11	– ^e	–	+ ^g	+ ^g
12	–	+ ^h
13	–	+ ^g	+ ⁱ
14	+	+ ⁱ	...
15	–	+	–	+	+
16	–	+	...	–
All, no. of patients with positive results/no. of patients with sample tested	5/16	0/1	0/3	0/0	6/6	1/4	7/8	3/4	1/1	3/5		

NOTE. Ind, indeterminate (PCR performed twice); –, negative; +, positive.

^a Nasal swab.

^b Negative for enterovirus but grew rhinovirus 16.

^c Urine.

^d Combined throat and conjunctival swab.

^e Specimen grossly bloody.

^f Nasopharyngeal swab.

^g Combined throat and rectal swab.

^h Combined conjunctival, throat, and rectal swab.

ⁱ Skin vesicle swab.

with poliomyelitis-like AFP experienced residual limb weakness and atrophy, and 75% of the patients with acute cardiac dysfunction had significant long-term neurologic sequelae. In contrast, all of the patients with aseptic meningitis recovered completely and without residual neurologic effects.

In our report, there were 9 specimens from the upper respiratory tract or lower gastrointestinal tract submitted for both EV-PCR and viral culture. The EV-PCR result was positive for all 9 specimens, and the viral culture result was positive for only 4 (44.4%) of the 9 specimens. No patient had a negative EV-PCR result and a positive viral culture result for the same specimen. We believe that EV-PCR is the preferred diagnostic modality because of its sensitivity and turnaround time. PCR testing of both throat and rectal swab specimens provided the diagnosis for every patient for whom these specimens were tested. There may be clinical circumstances in which testing of other specimens (blood, urine, or skin vesicle) may also be useful [9, 27, 35].

Enteroviruses can be detected by EV-PCR of upper respiratory or lower gastrointestinal tract specimens for several weeks after the onset of infection. However, in the context of a hospitalized patient with neurologic disease (especially en-

cephalitis or AFP), the report of negative results of EV-PCR of a CSF sample, combined with a positive result of EV-PCR of a throat and/or rectal swab sample, should prompt consideration of EV71 as the etiologic agent. One potential limitation of EV-PCR of upper respiratory tract specimens is the occasional cross-reaction with rhinoviruses. However, subsequent typing of the isolate or viral nucleic acid can distinguish the 2 viruses [15].

All of these clinical cases occurred in children with disease that was serious enough to require hospitalization. Milder cases may have occurred during this period. Other hospitalized patients with neurologic disease may not have received diagnoses, because the result of EV-PCR of the CSF sample was negative, and testing of samples from other sites was not performed.

There is no proven effective therapy for EV71 disease. Antiviral, steroidal, and intravenous immunoglobulin therapy have all been used for EV71 infection, but these treatments have not been studied in randomized, placebo-controlled trials [26, 35–38]. Intravenous immunoglobulin therapy was used for 3 patients in this series on the basis of initial diagnoses of myocarditis (in 2 patients) and atypical Guillain-Barré syndrome (in 1 patient). These clinical presentations actually rep-

Table 3. CSF parameters in patients with enteroviral type 71 infection.

Patient	Age	Time of lumbar puncture, no. of days from onset of illness	CSF parameters				CSF PCR result
			WBC count, cells/mm ³	RBC count, cells/mm ³	Glucose level, mg/dL	Protein level, mg/dL	
1	2 years	2	2075	14	56	69	-
2	5 years	4	76	8	126	56	-
3	10 days	1	1	200	68	78	+
4	6 months	2	228	43	71	52	-
5	5 years	10	2	1200	94	40	-
6	2 months	2	15	5100	57	59	+
7	3 months	2	6	1700	58	34	+
8	1 months	2	ND	ND	ND	ND	+
9	9 years	10	5	1110	60	66	-
10	3 months	3	406	0	54	91	-
11	7 months	8	ND	ND	ND	ND	-
12	7 weeks	2	240	250	49	107	-
13	7 weeks	4	205	63	41	65	-
14	3 months	1	6	288	50	49	+
15	2 years	2	55	95	68	39	-
16	2 years	15	11	0	51	44	-

NOTE. ND, not determined (because of CSF being grossly bloody; samples were sent for enterovirus PCR and culture only); -, negative; +, positive.

resented 2 cases of EV71-associated neurogenic acute cardiac dysfunction with pulmonary edema and 1 case of AFP, respectively. One of these patients died, 1 is quadriplegic and dependant on mechanical ventilation, and 1 has persistent flaccid paralysis of a lower extremity.

Transmission of EV71 infection is a public health concern. In a prospective family cohort study, the rate of household transmission of EV71 infection was 52% (176 of 339 patients). The rate of transmission among children aged <6 years was particularly high at 84% (89 of 106 children) [39]. There has been 1 report of nosocomial transmission of EV71 infection to 5 hospitalized patients [9]. Although enteroviruses spread efficiently by the fecal-oral route, there is some evidence that large-droplet respiratory transmission may also occur [39, 40]. At our institution, droplet isolation (mask, gown, and gloves) was recommended for patients with suspected EV71 infection.

EV71 disease should be considered in young children with aseptic meningitis, encephalitis, AFP, atypical Guillain-Barré syndrome, acute cardiac dysfunction, and/or pulmonary edema. Testing for other agents, such as West Nile virus or poliovirus, should be considered, depending on the epidemiologic context. To confirm the diagnosis of EV71 disease, CSF, throat, and rectal specimens should be tested by EV-PCR. Positive specimens should be subjected to additional testing, such as genotyping by VP-1 PCR or confirmation of culture-positive specimens by immunofluorescence using EV71-specific monoclonal antibodies. In this series, EV-PCR of specimens from the upper respiratory

and lower gastrointestinal tracts had the highest diagnostic yield. Potential therapies, including intravenous immunoglobulin, need to be studied in patients with serious EV71 disease. This may be best accomplished in the context of a large outbreak of disease. It is likely that EV71 circulates in other geographic areas of the United States and is not detected, because results of EV-PCR of CSF samples are negative, and throat and rectal swab specimens are not tested. Only a high index of suspicion for EV71 allowed us to identify many of these cases.

Increased awareness of EV71 disease and early testing of CSF, throat, and rectal samples may be beneficial as an early warning system of impending outbreaks of disease. Physicians need to be aware of this potentially severe and sometimes fatal poliomyelitis-like disease. As wild-type poliovirus is eradicated from the world, EV71 may emerge as the most common infectious cause of AFP in children.

Acknowledgments

We thank Dr. Paul Moe, whose clinical acumen allowed for the recognition of the initial case; Drs. Mark Abzug, Charles Daley, Nancy Madinger, Harley Rotbart, Eric Simoes, Jim Todd, and Ken Tyler, for their critical review of the manuscript; Wendy Tan (Centers for Disease Control and Prevention; Atlanta, GA), for technical assistance with the flavivirus PCR; and the staff at the Virology and Molecular Diagnostic Laboratories at The Children's Hospital (Denver, CO), for their assistance with this project.

Potential conflicts of interest. All authors: no conflicts.

References

1. Global Polio Eradication Initiative. Wild poliovirus weekly update. Available at: <http://www.polioeradication.org/casecount.asp>. Accessed 1 February 2007.
2. Baker A. Poliomyelitis. 16. A study of pulmonary edema. *Neurology* **1957**; *7*:743–51.
3. Ishimaru Y, Nakano S, Yamaoka K, Takami S. Outbreaks of hand, foot, and mouth disease by enterovirus 71: high incidence of complication disorders of central nervous system. *Arch Dis Child* **1980**; *55*:583–8.
4. MeNick J. Enterovirus type 71 infections: a varied clinical pattern sometimes mimicking paralytic poliomyelitis. *Rev Infect Dis* **1984**; *6*(Suppl 2): S387–90.
5. Alexander J Jr, Baden L, Pallansch M, Anderson L. Enterovirus 71 infections and neurologic disease—United States, 1977–1991. *J Infect Dis* **1994**; *169*:905–8.
6. Chang L, Huang Y, Lin T. Fulminant neurogenic pulmonary oedema with hand, foot, and mouth disease. *Lancet* **1998**; *352*:367–8.
7. Schmidt N, Lennette E, Ho H. An apparently new enterovirus isolated from patients with disease of the central nervous system. *J Infect Dis* **1974**; *129*:304–9.
8. Chang L, King C, Hsu K, et al. Risk factors of enterovirus 71 infection and associated hand, foot, and mouth disease/herpangina in children during an epidemic in Taiwan. *Pediatrics* **2002**; *109*:e88.
9. Gilbert G, Dickson K, Waters M, Kennett M, Land S, Sneddon M. Outbreak of enterovirus 71 infection in Victoria, Australia, with a high incidence of neurologic involvement. *Pediatr Infect Dis J* **1988**; *7*:484–8.
10. Ho M, Chen E, Hsu K, et al. An epidemic of enterovirus 71 infection in Taiwan. *New Engl J Med* **1999**; *341*:929–35.
11. Chan K, Goh K, Chong C, Teo E, Lau G, Ling A. Epidemic hand, foot, and mouth disease caused by human enterovirus 71, Singapore. *Emerg Infect Dis* **2003**; *9*:78–85.
12. Yan J, Wang J, Liu C, Yang H, Su I. An outbreak of enterovirus 71 infection in Taiwan 1998: a comprehensive pathological, virological, and molecular study on a case of fulminant encephalitis. *J Clin Virol* **2000**; *17*:13–22.
13. Rotbart H, Sawyer M, Fast S, et al. Diagnosis of enteroviral meningitis by using PCR with a colorimetric microwell detection assay. *J Clin Microbiol* **1994**; *32*:2590–2.
14. Yagi S, Schnurr D, Lin J. Spectrum of monoclonal antibodies to coxsackievirus B-3 includes type and group-specific antibodies. *J Clin Microbiol* **1992**; *30*:2498–501.
15. Nix W, Oberste MP, Pallansch MA. Sensitive, seminested PCR amplification of VP1 sequences for direct identification of all enterovirus serotypes from original clinical specimens. *J Clin Microbiol* **2006**; *44*: 2698–704.
16. Thompson J, Higgins D, Gibson T. CLUSTAL W: improving the sensitivity of progressive multiple sequence alignment through sequence weighting, position-specific gap penalties and weight matrix choice. *Nucleic Acids Res* **1994**; *22*:4673–80.
17. Brown B, Oberste M, Alexander J Jr, Kennett M, Pallansch M. Molecular epidemiology and evolution of enterovirus 71 strains isolated from 1970 to 1998. *J Virol* **1999**; *73*:9969–75.
18. U.S. Census Bureau. July 1, 2003, population estimates for metropolitan, micropolitan, and combined statistical areas. Available at: http://www.census.gov/population/www/estimates/Estimates%20pages_final.html. Accessed 6 August 2007.
19. Khetsuriani N, LaMonte-Fowlkes, Oberste M, Pallansch M. Enterovirus surveillance—United States, 1970–2005. *MMWR* **2006**; *55*:1–20.
20. Hayward J, Gillespie S, Kaplan K, et al. Outbreak of poliomyelitis-like paralysis associated with enterovirus 71. *Pediatr Infect Dis J* **1989**; *8*:611–6.
21. Tanel R, Kao S, Niemiec T, et al. Prospective comparison of culture vs genome detection for diagnosis of enteroviral meningitis in childhood. *Arch Pediatr Adolesc Med* **1996**; *150*:919–24.
22. Rotbart H, Ahmed A, Hickey S, et al. Diagnosis of enterovirus infection by polymerase chain reaction of multiple specimen types. *Pediatr Infect Dis J* **1997**; *16*:409–11.
23. Kessler H, Santner B, Rabenau H. Rapid diagnosis of enterovirus infection by a new one-step reverse transcription-PCR assay. *J Clin Microbiol* **1997**; *35*:976–7.
24. Ahmed A, Brito F, Goto C, et al. Clinical utility of the polymerase chain reaction for diagnosis of enteroviral meningitis in infancy. *J Pediatr* **1997**; *131*:393–7.
25. Kupila L, Vuorinen T, Vainiopää R, Martila R, Kotilainen. Diagnosis of enteroviral meningitis by use of polymerase chain reaction of cerebrospinal fluid stool, and serum specimens. *Clin Infect Dis* **2005**; *40*:982–7.
26. Chang L, Lin T, Hsu K, et al. Clinical features and risk factors of pulmonary oedema after enterovirus-71-related hand, foot, and mouth disease. *Lancet* **1999**; *354*:1682–6.
27. Li C, Yang M, Chen R, et al. Clinical manifestations and laboratory assessment in an enterovirus 71 outbreak in southern Taiwan. *Scand J Infect Dis* **2002**; *34*:104–9.
28. World Health Organization. Polio Lab Network Quarterly Update. Routine tests of CSF for poliovirus surveillance give low yield. Available at: http://www.who.int/immunization_monitoring/43.pdf. Accessed 6 August 2007.
29. van Vliet KG, Glimåker M, Lebon P, et al. Multicenter evaluation of the Amplicor enterovirus PCR test with cerebrospinal fluid from patients with aseptic meningitis. *J Clin Microbiol* **1998**; *36*:2652–7.
30. Tsao L, Lin C, Yu Y, Wang B. Microchip, reverse transcription-polymerase chain reaction and culture methods to detect enterovirus infection in pediatric patients. *Pediatr Int* **2006**; *48*:5–10.
31. Rittichier K, Bryan P, Bassett K, et al. Diagnosis and outcomes of enterovirus infections in young infants. *Pediatr Infect Dis J* **2005**; *24*:546–50.
32. Robinson C, Willis M, Meagher A, Giesecker K, Rotbart H, Glode M. Impact of rapid polymerase chain reaction results on management of pediatric patients with enteroviral meningitis. *Pediatr Infect Dis J* **2002**; *21*: 283–6.
33. Modlin J, Polk B, Horton P, Etting P, Crane E, Spiliotes A. Perinatal echovirus infection: risk of transmission during a community outbreak. *New Engl J Med* **1981**; *305*:368–71.
34. Chang L, Huang L, Gau S, et al. Neurodevelopment and cognition in children after enterovirus 71 infection. *New Engl J Med* **2007**; *356*: 1226–34.
35. Nolan M, Craig M, Lahra M, et al. Survival after pulmonary edema due to enterovirus 71 encephalitis. *Neurology* **2003**; *60*:1651–6.
36. Huang C, Liu C, Chang Y, Chen C, Wang S, Yeh T. Neurologic complications in children with enterovirus 71 infection. *New Engl J Med* **1999**; *341*:936–42.
37. McMinn P, Stratov I, Nagarajan L, Davis S. Neurological manifestations of enterovirus 71 infection in children during an outbreak of hand, foot, and mouth disease in western Australia. *Clin Infect Dis* **2001**; *32*:236–42.
38. Rotbart H, Webster AD; Pleconaril Treatment Registry Group. Treatment of potentially life-threatening enterovirus infections with pleconaril. *Clin Infect Dis* **2001**; *32*:228–35.
39. Chang L, Tsao K, Hsia S, et al. Transmission and clinical features of enterovirus 71 infections in household contacts in Taiwan. *JAMA* **2004**; *291*:222–7.
40. Morens D, Pallansch M. Epidemiology. In: Rotbart H, ed. *Human enterovirus infections*. Washington, DC: American Society for Microbiology, **1995**:3–23.

Note added in proof. Since this article was written, we have identified and confirmed 4 additional cases of EV71-associated neurologic disease.